



# Definitive Management Option of Pelvic Ring Injury

Mohammad Zaim Chilmi<sup>1</sup>, Ismail Hadisoebroto Dilogo<sup>2</sup>

<sup>1</sup>Department of Orthopaedic and Traumatology, Universitas Airlangga, Dr. Soetomo General Hospital, Surabaya, Indonesia

<sup>2</sup>Department of Orthopaedic and Traumatology, Universitas Indonesia, Cipto Mangunkusumo General Hospital, Jakarta, Indonesia

## ABSTRACT

Pelvic ring injury is a rare condition with the incidence of hip fracture about 3% to 8% of all fractures. However, the majority of pelvic fracture patients have a high morbidity rate that could threaten their survival. The majority cause of hip fracture is high energy blunt trauma and is related to polytrauma incident. The main goals of management for pelvic ring injury are to restore the form and stability of the pelvic. The main goal is to prevent nonunion and malunion, which lead to chronic pain and disability.

This review is focused on the strengths and weaknesses of the management option, approach and complication for pelvic ring fracture surgery. Complications of pelvic ring fracture surgery are bleeding, nerve damage, DVT, pulmonary embolism, soft tissue injury, sepsis, and malunion of the pelvis and nonunion. Management for pelvic ring fracture surgery is used based on the location and configuration of the fracture, implant availability, surgeon's preference, and experience.

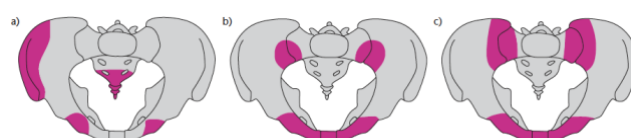**Keywords:** *Pelvic Ring Fracture, pelvic ring injuries, Approaches Pelvic Fracture, Management Pelvic Fracture*

## Introduction

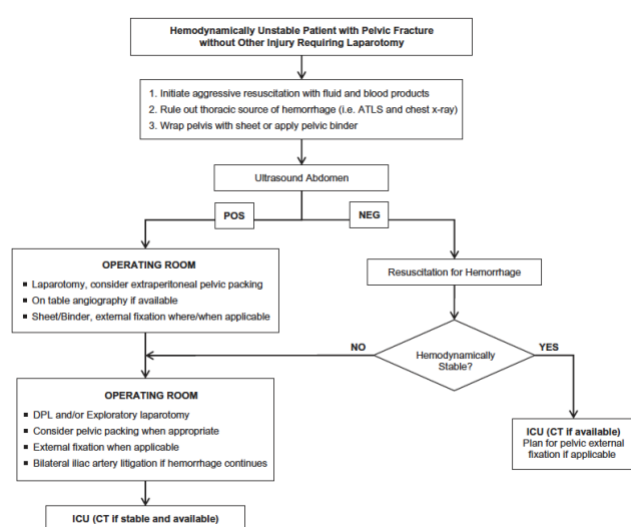
The incidences of pelvic ring fractures are ranged from 0.3%-6% from all types of fractures and around 20% in multitrauma cases.<sup>1,2</sup> Pelvic ring injury is associated with a high morbidity rate such as loss of functional movement, difficulties with daily tasks, and poor mental health<sup>3</sup>. In the United Kingdom, the mortality rate of pelvic ring injury patients was reported to be around 7.3 percent during hospitalization and 14.2 percent after three months of injury.<sup>4</sup>

Pelvic ring injuries are associated with major bleeding which may originate from the vein, artery or bone. Lumbosacral retroperitoneal venous plexus is the most prevalent site of bleeding, with gluteal artery injuries being less common. The visceral organ of the belly and pelvis and the L5 nerve root, are also at risk.<sup>5</sup>

joint to the vertical shear stress is described as a Type C Injury.<sup>6</sup> Type C injury is more complex and further classified based on the severity of its instability. Unilateral lesion is C1, bilateral lesion with one side vertically stable but unstable on the other is C2 and bilateral vertical instability lesion is classified as C3. Type C1 is further divided into several subgroups based on the type of posterior ring injuries. Type C1-1 is associated with ilium fracture, type C1-2 is associated with sacroiliac dislocation meanwhile type C1-3 is with sacral fracture.<sup>7,8</sup>



**Fig 2.** Pelvic ring injury based on AO/CCF (Comprehensive Classification of Fracture). a) Type A fracture (injury of the anterior ring or iliac crest or sacral bone below the S.I. joint). b) Type B fracture (anterior ring injury and posterior ring partial lesion). c) Type C fracture (total interruption of the posterior ring and possible injury to the anterior ring)<sup>9</sup>.



## Definitive Management of Pelvic Ring Injury

The management of pelvic ring injury has evolved over the past 75 years. In earlier days, conservative or non-operative management has been the mainstay of pelvic fracture due to the high rate of surgical mortality. However, after a deeper understanding of the basics of polytrauma, damage control concept and resuscitation, the trend has shifted to operative management in recent years. Furthermore, non-operative management of unstable pelvic ring injury is associated with unsatisfying outcomes and malunion, discomfort, and leg length discrepancy.<sup>10</sup>

The main goals of treatment for pelvic ring injuries are to re-obtain the ring shape of the pelvis and maintain its stability. The long-term goal is to prevent nonunion and malunion, which may lead to chronic pelvic pain and dysfunction.<sup>10</sup> In

## Classification of Pelvic Fractures

According to the classification system by AO/ASIF, pelvic ring injuries are divided into three types, A, B, and C. Sacral transverse fractures, fracture of iliac wing, and avulsion fractures are stable Type A injuries. Type B injuries can be described as rotational instability, with stable posterior structures and vertically stable. Complete disruption of the posterior sacroiliac

determining the course of the treatment for the patients, it should be based on the fracture pattern and the mechanism of injury. Other considerations, including patient age, comorbidities, and level of mobility prior to injury should also be profiled.<sup>11</sup>

The management of pelvic fracture should be started before the patient arrived at the hospital. Suspicion of pelvic ring injury should be increased if there are some bruises on the flank or lower abdomen. Initial care such as early diagnosis, bleeding control through pelvic binder, and hemodynamic restoration should be performed as early as possible. In the initial phase, obtaining and maintaining the hemodynamically stable condition is the most critical issue.<sup>12</sup>

Pelvic binder, C-clamp and anterior frame can be used temporarily when the patient was hemodynamically unstable to reduce the relative volume of the pelvic cavity. In the 1980s and early 1990s, external fixators were intended to be the definitive treatment option for open book injuries. Currently, it is utilized as a framework to stabilize all pelvic ring injuries to control the fractures fragments and reduce bleeding. In the last decade, external fixators have increasingly been used as temporary devices in patients with hemodynamic instability who require temporary pelvic ring rigidity, ostensibly to reduce retroperitoneal bleeding.<sup>10,13</sup> As the temporary fixation, external fixation can be utilized until the patient's hemodynamic status have stabilized. After which, the definitive internal fixation surgery can take place, which took about 5-7 days on average.<sup>14</sup> External fixation is preferred as a definitive treatment during the condition where internal fixation is not feasible such as in open pelvic fractures where the risk of contamination is severe. Pelvic external fixation allows some degree of mobilisation for the patients while it is successful in preventing rotational displacement in unstable fractures. However, the stability provided by the external fixation is not sufficient to permit the patient to ambulate especially in

both rotationally and vertically unstable injuries<sup>1,15</sup>

### Internal Fixation Surgery for Pelvic Ring Injury

Studies have documented the superior results of the internal fixation compared to either conservative surgery or external fixation devices. It provides excellent fracture reduction and better biomechanical stability enabling better healing and faster ambulation. Others have also recommended that pelvic fracture surgery should be done in <14 days after the initial incident. Early fracture fixation allows better fracture reduction and provides superior fracture stability, thus a better prognosis.<sup>10</sup>

The traditional method of internal fixation surgery is through open reduction surgery which can be achieved through various approaches. Open reduction and internal fixation (ORIF) is used to treat fractures with wide displacement such as symphyseal widening greater than 2.5 cm and wide sacroiliac joint dislocation. The important concept of treating a pelvic ring injury is to obtain and maintain both anterior ring stability and posterior ring stability. Failure to recognize and treating some instability in either side may lead to a catastrophic event. Therefore, the type of instability caused by a pelvic ring injury determines definitive fixation.<sup>16</sup>

#### **Type A Fracture**

There is no clear indication for surgery if there is no rotational or vertical instability (Type A). Stabilization of the anterior ring with external or internal fixation is useful to treat Type B fractures. In vertically and rotationally unstable fractures, both the anterior and posterior rings should be stabilized (Type C).<sup>17</sup>

#### **Type B Fracture**

With intact posterior pelvic structures, rotational instability without vertical instability is found in Type B1 fractures. The 'open book' injury that might occur after anteroposterior compression (APC) force to the pelvis is the most common type B1 fracture. A slightly displaced (< 2.5 cm) pubic

symphysiolysis has intact pelvic ligaments and might be treated without surgery. On the other hand, displaced injury (>2.5 cm) may also affect the posterior ligament structures such as sacrospinous and sacrotuberous ligaments, pelvic floor structures, and sacroiliac ligaments.<sup>13</sup> Evaluation of the integrity of posterior ring elements is paramount, especially when differentiating type B1 with B2 and B3 fractures since posterior fixation is indicated in the latter. The extent of the posterior ring injury may span from simple sacroiliac dislocation, ilium fracture or sacroiliac joint fracture-dislocation which is usually called as crescent fracture. Iliac or crescent type fracture is treated based on the remaining iliac fragment attached to the sacrum. The usual treatment of choice is anterior plating using two short 3.5 mm plates in the opening of the ilioinguinal approach is another form of posterior fixation. This type of posterior hip ring injury can be well stabilized by classical reduction and fixation of the dislocated plate or fracture close to the sacroiliac joint. Be aware that the L5 nerve root might be damaged by excessive retraction and/or misplacement of the retractor or plate (1.5cm medial to the S.I. joint).<sup>13</sup>

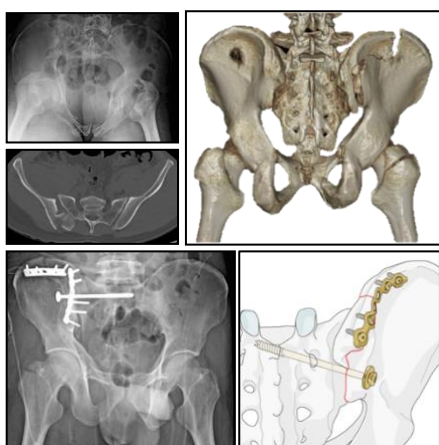


Figure 3. Male, 33 years old, with Crescent fracture Day type 2, treated with a combination of iliosacral screw to fix the sacroiliac joint and posterior iliac wing plating to fix the fractured ilium. (case is courtesy of Rahat Jayarabhan)

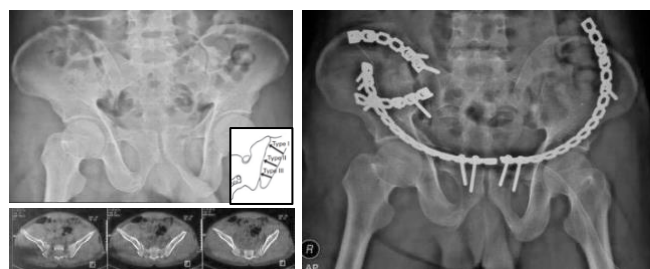


Figure 4. Case with Crescent fracture type 1, where the crescent fragment was fixed using 3.5 curved reconstruction plate through a lateral window approach. Minimal invasive approach were used to fix the pubic fracture.

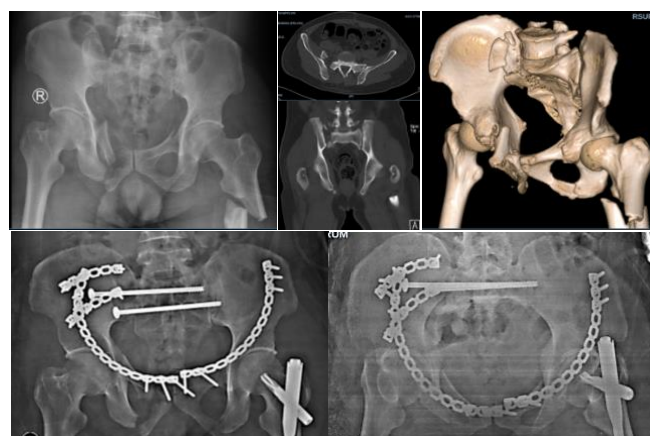


Figure 5. Male 43 years old with crescent fracture type 3 and sacral fr C1.3, the sacral-iliac comminutive displaced fragment was stabilized using plate meanwhile the sacroiliac joint and sacrum were fixed using two trans-iliac screws (S1 and S2 screws).

### Type C Fracture

A vertical shear fracture is a type C fracture whose pattern is mechanically unstable. The mechanism of injury caused by the high energy/shear force used, the pelvic ring has been completely disrupted. The mechanism can be through one or both posterior (sacroiliac) complexes, this injury can be single or both sides. The soft tissues of the pelvic floor and the ligamentous structures that support it are disrupted.<sup>13,18</sup>

Internal and external fixation procedures can be used to stabilize rotational and vertical instability in hip fractures [Orthopedic Trauma Association (OTA) 61-C, Tile C]. Because it does not withstand pressure in the posterior pelvic ring, anterior pelvic ring external fixation (ExFix) alone

can't give sufficient pelvic stabilization. When paired with posterior pelvic ring internal osteosynthesis, such as a sacral bar, sacroiliac joint plate (S.I.) fixation, or trans iliosacral lag screw, better pelvic stabilization is achieved.<sup>19</sup>

Type C fractures are vertically shear mechanically unstable fracture types. Due to the nature of the injury (high-energy/shearing injury), the pelvic ring has been entirely disrupted. These fractures might be unilateral or bilateral. The soft tissue of the pelvic floor and the ligamentous structures that support it are disrupted<sup>13</sup>. The posterior weight-bearing SI joints integrity is crucial to the pelvic ring stability. However, biomechanical studies have revealed that the pelvic ring stability in Type C injuries, in general, are depending on the symphysis pubis and pubic rami, accounting for about 40% of the ring overall stability. In an unstable Type C injury, an external fixator placed anteriorly did not provide sufficient stability for safe mobilization of the patient without the possibility of fracture re-displacement, according to biomechanical tests<sup>7</sup>

In some cases, open reduction is not necessary. Closed reduction and internal fixation may have a role if the initial displacement is small and definitive surgery can be performed as early as possible. Push-pull techniques with the manual method or a traction device (e.g., S.T.A.R Frame) might help with patients with large habitus. Percutaneous cannulated screw fixation reduces the wound problems due to large surgical wounds.<sup>13</sup> In recent years, iliosacral screw percutaneous for posterior ring fixation has become distinguished choice. This procedure is especially useful for cases with associated skin injury near the incision site.<sup>1,20</sup>

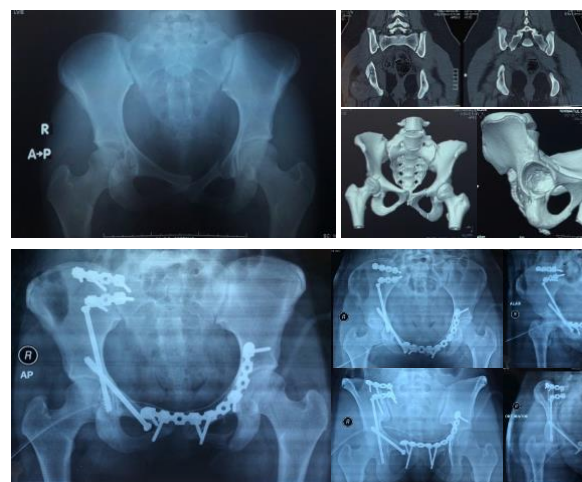


Figure 6. Female, 17 years old, M.V.A. being hit by the truck (a) Initial AP Xray showing disruption at the right sacroiliac joint, suspected fracture line at right acetabulum and left pubic rami disruption. (b) CT images showing vertical translation of right hemipelvis, transverse acetabular fracture. (c) Post-operative images after ORIF at right SI Joint and left pubic rami and both column acetabular screw for the transverse fracture.

### Surgical Approach

Depending on the fracture type, the surgeon may need to fix the anterior ring only, posterior ring only or both. The anterior pelvic ring can be approached using the Pfannenstiel, Modified Stoppa, or Ilioinguinal approach. Meanwhile, the posterior approach is usually only needed when the reduction of the SI joint is unobtainable through closed means or when there is a comminuted sacral fracture accompanies it.<sup>1</sup>

### Approaches to the Anterior Ring

#### **Pfannenstiel approach**

The Pfannenstiel approach is suitable for the pure pubic symphysiolysis case where only a small amount of exposure is needed. This approach can also be used for retroperitoneal packing for patients with unstable hemodynamic pelvic injury<sup>21</sup>.

The patient is in a supine position. The curved or straight incision is made 2 cm above the pubic symphysis and superior pubic ramus. The midline incision should be centered and protrude the outer inguinal ring on both sides. Another option, a direct midline incision that can be made

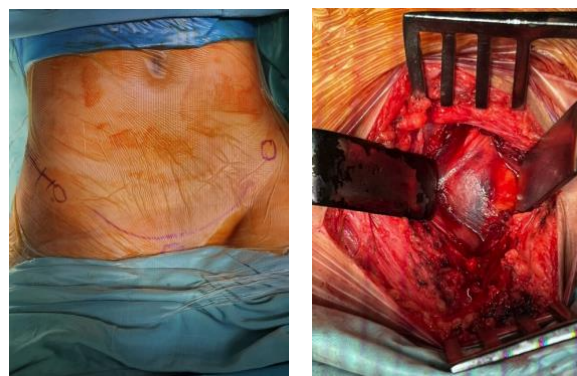
about 10 cm above the lower part of the pubic symphysis.<sup>21</sup> The anterior plating approach described by Hirvensalo, Lindahl, and Hirvensalo provides excellent access to the interior surface of the pubic ramus and the acetabulum anterior column through the lower midline or Pfannenstiel incision.<sup>7,22</sup>

### **Modified Stoppa Approach**

The Modified Stoppa (anterior intrapelvic) approach was introduced to treat the acetabular and pelvic injury; it provides excellent exposure of the pelvic brim, which is the best place for screw fixation.<sup>23</sup> This approach also reveals the superior and inferior branches of the pubic bone and the four sides of the acetabulum.<sup>21</sup>

The surgery was performed in the supine position, with both hips and knees were bent slightly to relax the iliopsoas muscle. In the midline between the rectus abdominis muscle from the umbilicus to the symphysis, a vertical skin incision was made, and without any sharp dissection, the rectus abdominis was withdrawn laterally from the symphysis to expose the preperitoneal space and the pubic symphysis. The transverse abdominal muscles are dissected from the peritoneal sac and manipulated upward and medially from the fracture site. The pelvic ring is exposed around the superior pubic ramus adjacent to the joint. Hoffman retractor is inserted in the suprapubic branch to reflect away the anterior abdominal wall from the sac. The Deaver retractor is used to protect the external iliac vessels. After ligation, look for any vascular anastomosis, including corona mortis if possible. The iliopectineal fascia is cut and the psoas major muscle is reflected away to reveal the pelvic iliac pubic line and the quadrilateral surface to the bone and medial border of the sacroiliac joint. If necessary, the skin incision can be extended to the other side of the pelvic ring to provide better exposure. Standard pelvic reduction forceps, intraoperative bone extraction, and temporary external fixation of the injured lower limbs can reduce fracture and dislocation of the anterior ring. A 3.5mm

reconstruction plate is placed on the suprapubic ramus or the inner side of the pelvic rim (infrapectineal).<sup>23,24</sup>



**Fig 7.** Modified Stoppa Approach (A) skin incision (B) corona mortis and iliopectineal fascia identification

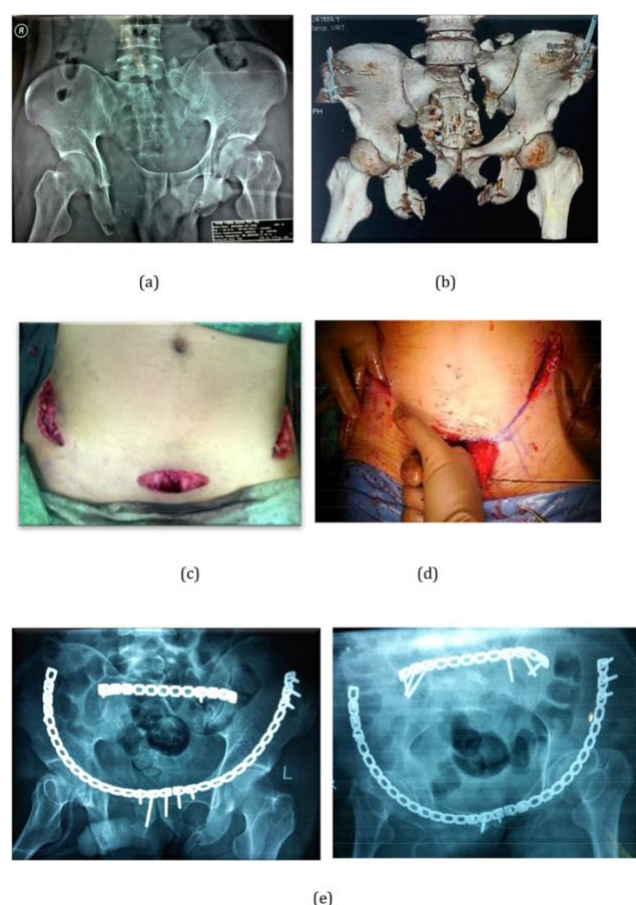
### **Ilioinguinal Approach**

The ilioinguinal approach as described by Letournel in 1961 is the approach of choice for the exposure, reduction, and fixation of fractures involving the anterior column of the acetabulum and the inner surface of the innominate bone. The ilioinguinal approach requires the opening of the inguinal canal and the mobilization of the external iliac vessels with the subsequent development of 3 working windows. The first or lateral window extends from the sacroiliac joint to the lateral aspect of the iliopsoas muscle, providing access to the sacroiliac joint, the internal iliac fossa, and the proximal pelvic brim. The second or middle window is defined laterally by the medial aspect of the iliopsoas muscle and the femoral nerve and medially by the external iliac artery, offering access to the distal pelvic brim, the quadrilateral surface, the anterior acetabular wall, the iliopsoas gutter, and the iliopectineal eminence. The third or medial window is developed between the external iliac vein and the lateral aspect of the rectus abdominis muscle, allowing access to the space of Retzius, the pubic symphysis, and the superior pubic ramus from the pubic tubercle to the pectineus recess. Extensile maneuvers can offer broader exposure of the anterior wall, the

anterior hip capsule, the quadrilateral surface, and the external iliac fossa.<sup>25,26</sup>

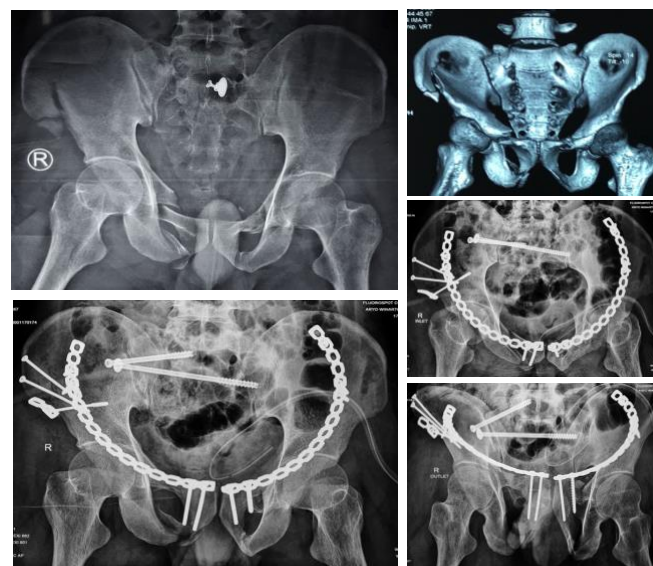
### Minimal Invasive Approach Variants

Minimally invasive modified Stoppa and lateral Ilioinguinal window approach was used for selected patients that presented with an anterior pelvic injury. Exposing the pubic tubercle and superior pubic rami at its anterosuperior part provided a decent space for plate placement and the use of reduction tools. A lateral window was made from the iliac tubercle to the anterior superior iliac spine and connected to the medial window through subperiosteal tunnel. Periosteal stripping at both sites of the incisions was necessary for creating this tunnel to prevent injury to neurovascular structures. This approach decreases the duration of surgery and blood loss without compromising the quality of reduction and functional outcome in patients.<sup>27</sup>



**Fig 8.** A 36 years old male with unstable pelvic fracture, MT C3 Type right anterior column (a) Preoperative anteroposterior pelvic radiograph showing fracture of right superior and inferior pubic

rami, left anterior column acetabular fracture, left sacral fracture and vertical instability of left hemipelvis; (b) 3D reconstruction CT Scan showing a clearer image of the fracture pattern. (c) Modified Stoppa and lateral ilioinguinal approach, showing the extent of the incision while leaving the second (middle) window intact; (d) Blunt finger dissection subperiosteally connecting the tunnel from both incisions; (e) postoperative anteroposterior pelvic radiograph showing satisfactory reduction of pelvic fracture and anatomical reduction of the left anterior acetabular column.



**Fig 9.** 32 years old male with sacral dysmorphism. The initial x-ray showed right SI Joint disruption, right iliac wing fracture, and bilateral pubic rami fracture. Treatment strategies consist of minimal invasive ORIF of bilateral pubic rami, fixation of the ilium through a lateral window and iliosacral screw fixation for the SI joint. CT Scan is mandatory to plan screw trajectory in sacral dysmorphism

## Approaches to the Posterior Ring

### Anterior approach to the SI joint

The anterior approach directly exposes the S.I. joints and at the same time exposes the anterior pelvic ring. The anterior approach is an ideal method for the treatment of sacroiliac dislocation as it offers direct exposure of the SI joint. Patients mostly are lying on their backs with a small cushion on the affected side to facilitate the exposure. The lateral decubitus position with the affected side up also could be an option. In this position, gravity helps to pull the abdomen, especially in obese patients. The incision should be made approximately 1 to 2 cm near the subcutaneous edge of the pelvic wing and 5 cm

proximal to the uppermost pelvic wing. If better visualization is needed, the incision can be extended 5-8 cm in the ASIS, parallel to the lateral border of the sartorius muscle. ASIS osteotomy can internalize the abdominal muscles and better expose the S.I. joint<sup>21</sup>. The main disadvantage is this approach is not suitable for sacral fractures and some crescent fractures treatment.

### **Posterior approach to the S.I. joint and lateral sacrum**

The posterior approach gave excellent access to the pelvis's external platform and allowed direct adjustment of the fracture and the dislocation of the SI joint through the iliac outlet. This method can also directly observe and be useful in lateral sacral injuries treatment. This approach is suitable for S.I. tears, sacrum fractures, posterior pelvic wing fractures, and crescent fractures. In particular, it is of great use for posterior annulus injuries with significant translational instability. Access is straightforward, however soft tissue injuries such as Morelle-Lavalle injuries should be considered and other serious intracranial, abdominal, or thoracic injuries should be noted as the prone position is required. The surgery should be postponed until the related injuries have healed and the soft tissues have recovered.<sup>28</sup>.

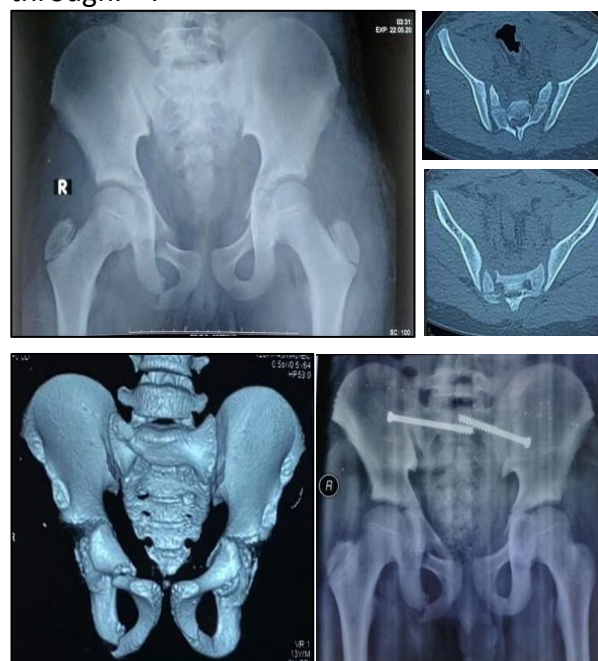
Using parallel mats that extend from the sides of the chest to the abdomen, lie the patient back on a translucent table. Alternatively, the patient can lie on his side with the affected side facing up. However, the weight of the patient can make it difficult to reposition and maintain the displaced fracture. Make a skin incision according to the location of the fracture. In case of simple dislocations of the SI joint or fractures involving the outer platform of the iliac bone, an incision on the lateral curve is made of the PSIS parallel to the edge of the iliac crest. For sacral fractures, the incision is inside of the PSIS<sup>21</sup>

The main disadvantage of this method is that PSIS covers most of the SI joints. Confirm the reduction of the SI joint by palpating the ischial notch, but it can only be checked directly in the

lower area. Early complications are not uncommon, especially high-energy fractures associated with Morrel-Laval injuries.<sup>21</sup>.

### **Sacral Approach**

The posterior sacral approach can be used for centrally displaced sacral fractures or bilateral sacral fractures. A tension plate for the posterior pelvic ring is also useful. Patient in the prone position using a cushion. A midline skin starting from the lower part of the lumbar spine up to the sacral promontory is made. Alternatively, a lateral incision below the PSIS and above the sacral promontory can be made. When the lumbar fascia is found, an incision is made near the median and the lumbar muscles are mobilized laterally. For less invasive methods, three small incisions are available. Use a small central incision or an incision around the center to expose and reposition the fracture and make two diagonal incisions on the sides of the PSIS to allow the tension band to pass through.<sup>21</sup>.



*Fig.10 Children, 13 years old with left sacroiliac joint disruption, right sacral fracture and pubic rami fracture (a) initial x-ray; (b & c) CT Scan showing right transforaminal sacral fracture and disruption of left SI Joint; (d) postoperative x-ray after percutaneous screwing*



## Complications

According to reports, the complication rate is 25%, most of which are due to surgery rather than the initial injury.<sup>17</sup> These complications include bleeding, nervous system damage (from fracture reduction and surgery to possible compression and damage nerve roots around the pelvis), DVT, pulmonary embolism, soft tissue damage, necrosis and sepsis, malunion of the pelvis and nonunion.<sup>9,13</sup>

External fixation is associated with high complication rates, such as infection at the injection site, loose needles, and heavy frames that make it difficult to move and take care of the hip joint.<sup>14,28</sup> Complications usually are found in high-energy fractures which require major surgery, which can also be a cause of the disease. It makes it difficult to pinpoint whether the injury or the treatment as the basis for each complication.<sup>4</sup>

One of the more severe complications that could happen after open pelvic fractures and/or pelvic fixation is infection. A study by Sagi et al reported that 2.9% of patients with surgical fixation had deep wound infections after surgery, and patients with preoperative vascular embolization or had a body mass index greater than 30 were particularly at greater risk. Other risk factors for infection are diabetes, long surgery time, extended care in the intensive care unit, and urogenital or abdominal injury. High-risk patients should be closely observed and deep pelvic infections should be treated with a low suspicion index. Treatment includes high doses of systemic antibiotics.<sup>4</sup>

Due to prolonged inactivity, trauma to the vascular endothelium, and surgical operations, patients with pelvic fractures are at a greater risk for complications such as venous thromboembolism (VTE), including deep vein thrombosis (DVT) and pulmonary embolism (PE). In England, the incidence of DVT and PE after pelvic and acetabular fractures surgery was 10% and 5%, respectively. To minimize the risk of VTE,

one of the recommendations is to start thrombosis prophylaxis as early as possible in accordance with the existing guidelines. Anticoagulation therapy should be initiated within 24 hours after injury or after hemodynamic stability is achieved.<sup>4</sup>

Among pelvic fractures patients, 3.7% of cases had genitourinary system damage, which later leads to sexual and urinary dysfunction. Sexual dysfunction, in particular, is found to be a predictor of poor quality of life, with proportions of women and men reaching 43.8% and 52.1%, respectively. Urethral injuries are also common, it is found in about 1.6% to 25% of patients with pelvic fractures, and can lead to recurrent strictures in men, the incidence of which varies depending on the treatment used. According to a Canadian study, compared to the general population, patients who have undergone surgery for pelvic fracture are at higher risk (about 3 times more than the average person) to require additional surgery due to stress urinary incontinence.<sup>4,29</sup>

In the future, about 64% of pelvic ring injury patients will have some complaint about pelvic pain after chronic trauma, even 52 months after the injury. Anxiety and depression have a moderate to strong correlation with the chronic phase of this pain. Compared with the general population, the quality of life of these patients is often lower, including long-term decline in physical function, difficulties in activities of daily living, and poor mental health.<sup>4,30</sup>

## Conclusion

Management of pelvic ring injuries should be individualized based on the pattern of fracture. Evaluation of anterior and posterior stability should be evaluated before deciding the course of definitive treatment. The choice of fixation whether it is anterior, posterior or both should be determined based on the stability.

## Acknowledgement

The authors would like send gratitude to Yoshi Pratama Djaja, MD and Jifaldi AMD Sedar, MD for the kind supports during the writing of this paper.

## References

- Halawi MJ. Pelvic ring injuries: Surgical management and long-term outcomes. *J Clin Orthop Trauma* [Internet]. 2016;7(1):1–6.
- Cole PA, Gauger EM, Anavian J, Ly T V., Morgan RA, Heddings AA. Anterior pelvic external fixator versus subcutaneous internal fixator in the treatment of anterior ring pelvic fractures. *J Orthop Trauma*. 2012;26(5):269–77.
- Banierink H, Reininga IHF, Heineman E, Wendt KW, ten Duis K, IJpma FFA. Long-term physical functioning and quality of life after pelvic ring injuries. *Arch Orthop Trauma Surg*. 2019;139(9):1225–33.
- Mostafa AMHAM, Kyriacou H, Chimutengwende-Gordon M, Khan WS. An overview of the key principles and guidelines in the management of pelvic fractures. *J Perioper Pract*. 2020;
- Gordon WT, Fleming ME, Johnson AE, Gurney J, Shackelford S, Stockinger ZT. Pelvic fracture care. *Mil Med*. 2018;183:115–7.
- Langford JR, Burgess AR, Liporace FA, Haidukewych GJ. Pelvic fractures: part 1. Evaluation, classification, and resuscitation. *J Am Acad Orthop Surg*. 2013 Aug;21(8):448–57.
- Lindahl J, Hirvensalo E. Surgical treatment of pelvic ring fractures. 2008;31:42–7.
- Isler B, Ganz R. Classification of pelvic ring injuries. *Injury*. 1996;27 Suppl 1:S-A3-12.
- Küper MA, Trulson A, Stuby FM, Stöckle U. Pelvic ring fractures in the elderly. *EFORT Open Rev*. 2019;4(6):313–20.
- Witvliet MJ, Ping Fung Kon Jin PH, Goslings JC, Luitse JS, Ponsen KJ. Historical treatment results of pelvic ring fractures: A 12-year cohort study. *Eur J Trauma Emerg Surg*. 2009;35(1):43–8.
- Langford JR, Burgess AR, Liporace FA, Haidukewych GJ. Pelvic fractures: part 2. Contemporary indications and techniques for definitive surgical management. *J Am Acad Orthop Surg*. 2013 Aug;21(8):458–68.
- Coccolini F, Stahel PF, Montori G, Biffl W, Horer TM, Catena F, et al. Pelvic trauma: WSES classification and guidelines. *World J Emerg Surg* [Internet]. 2017;12(1):1–18.
- Gray A, Chandler H, Sabri O. Pelvic ring injuries: classification and treatment. *Orthop Trauma*. 2018;32(2):80–90.
- Ismail HD, Lubis MF, Djaja YP. The outcome of complex pelvic fracture after internal fixation surgery. *Malaysian Orthop J*. 2016;10(1):16–21.
- Lee C, Sciadini M. The Use of External Fixation for the Management of the Unstable Anterior Pelvic Ring. *J Orthop Trauma*. 2018 Sep;32 Suppl 6:S14–7.
- Marecek GS, Scolaro JA. Anterior Pelvic Ring: Introduction to Evaluation and Management. *J Orthop Trauma*. 2018;32(9):8–10.
- Wong JML, Bucknill A. Fractures of the pelvic ring. *Injury*. 2017;48(4):795–802.
- Moon DH, Kim NK, Won JS, Choi JS, Kim DH. Outcome of Surgical Treatment of AO Type C Pelvic Ring Injury. *Hip Pelvis*. 2014;26(4):269.
- Mcdonald E, Theologis AA, Horst P, Kandemir U, Pekmezci M. When do anterior external or internal fixators provide additional stability in an unstable (Tile C) pelvic fracture? A biomechanical study. *Eur J Trauma Emerg Surg*. 2015;41(6):665–71.
- Iorio JA, Jakoi AM, Rehman S. Percutaneous Sacroiliac Screw Fixation of

- the Posterior Pelvic Ring. *Orthop Clin North Am.* 2015 Oct;46(4):511–21.
21. Tile M, Helfet DL, Kellam JF, Vrahas M. Fractures of the Pelvis and Acetabulum - Principles and Methods of Management. Fourth Edi. AO Foundation, Clavadelerstrasse 8, 7270 Davos Platz S, editor. Georg Thieme Verlag, Rüdigerstrasse 14, 70469 Stuttgart, Germany, and Thieme New York, 333 Seventh Avenue, New York, NY 10001, USA; 2015.
  22. Becker SC, Holstein JH, Pizanis A, Pohlemann T. [Anterior approaches to the pelvic ring]. *Unfallchirurg.* 2013 Mar;116(3):198–204.
  23. Oh HK, Choo SK, Kim JJ, Lee M. Stoppa approach for anterior plate fixation in unstable pelvic ring injury. *CiOS Clin Orthop Surg.* 2016;8(3):243–8.
  24. Wu H, Zhang L, Guo X, Jiang X. Meta-analysis of modified Stoppa approach and ilioinguinal approach in anterior pelvic ring and acetabular fractures. *Med (United States).* 2020;99(4).
  25. Tosounidis TH, Giannoudis VP, Kanakaris NK, Giannoudis P V. The Ilioinguinal Approach. *JBJS Essent Surg Tech.* 2018;8(2):e19.
  26. Fensky F, Lehmann W, Ruecker A, Rueger JM. Ilioinguinal Approach: Indication and Technique. *J Orthop Trauma.* 2018 Aug;32 Suppl 1:S12–3.
  27. Ismail HD, Djaja YP, Fiolin J. Minimally invasive plate osteosynthesis on anterior pelvic ring injury and anterior column acetabular fracture. *J Clin Orthop Trauma [Internet].* 2017;8(3):232–40.
  28. Kalia R, Agrawal A. Surgical approaches of the pelvis. *J Orthop Traumatol Rehabil.* 2014;7(1):14.
  29. Li P, Zhou D, Fu B, Song W, Dong J. Management and outcome of pelvic fracture associated with vaginal injuries: A retrospective study of 25 cases. *BMC Musculoskelet Disord.* 2019;20(1):1–7.
  30. Suzuki T, Shindo M, Soma K, Minehara H, Nakamura K, Uchino M, et al. Long-term functional outcome after unstable pelvic ring fracture. *J Trauma.* 2007 Oct;63(4):884–8.